



# Saved by the Pupillometer! – A role for pupillometry in the acute assessment of patients with traumatic brain injuries?

John A. Emelifeonwu<sup>a</sup>, Kirsten Reid<sup>b</sup>, Jonathan KJ Rhodes<sup>b</sup>, and Lynn Myles<sup>a</sup>

<sup>a</sup>Department of Neurosurgery, Western General Hospital, Edinburgh, UK; <sup>b</sup>Department of Neurointensive Care, Western general Hospital, Edinburgh, UK

## ABSTRACT

There is good evidence that pupil reactivity is useful for prognostication in acute head injuries. Despite this, most pupil assessments are subjective and are performed by physicians who may not be experts. They can therefore be unreliable. We present a case of a patient with seemingly irreversible demise from an acute traumatic subdural haematoma. This was determined by assessment of his pupils, which were non-reactive to light at the time of arrival to the neurosurgical theatre. He was transferred to the neurointensive care for brainstem death testing, where assessment by objective pupillometry determined that his pupils were in fact reactive. He made a good recovery following subsequent surgery to evacuate his subdural haematoma. We propose the widespread adoption of objective pupillometers in the assessment of acute head-injured patients and offer our case as an example of how an objective and accurate assessment can make a difference to patients' outcome.

## ARTICLE HISTORY

Received 28 February 2017  
Revised 18 October 2017  
Accepted 14 January 2018  
Published online 1 February 2018

## KEYWORDS

Traumatic brain injury; TBI; acute subdural haematoma; neuroICU; pupillometer; NPi; uncal herniation

## Introduction



Accurate and rapid neurological assessment of patients with traumatic brain injuries (TBIs) can aid early detection of raised intracranial pressure (ICP) and impending neurological deterioration. The pupillary light reflex is one such assessment, which exploits the anatomical proximity of the third cranial nerve to the medial temporal lobe to predict imminent or actual uncal herniation (coning) in patients with raised ICP. It is also a useful prognostic indicator in TBIs, which in combination with Glasgow Coma Scale (GCS) can predict survival and long-term outcomes (1–3). In the clinical setting, the pupillary light reflex is most commonly tested manually by clinicians and nurses. However, there are inter-observer disparities in interpreting the results, especially in the extremities of pupil size (4). This has led to the development of automated objective pupillometers (OPs). These computer-based digital video devices use infrared light to illuminate the eyes. Pupil reactivity is then assessed by a digital camera and is given a numerical value – neurological pupil index or NPi – which can then be interpreted. OPs are easy to use and the objectiveness by which they measure pupillary size, reactivity and symmetry reduces inter-user interpretation bias. It is increasingly used as an assessment tool in the neurointensive care (neuroICU) setting; however, uptake by other clinicians remains slow. In this article, we describe the case of a patient with TBI who was presumed to have ‘coned’ because he had non-reactive, dilated pupils when assessed. Subsequent OP, however, revealed that his pupils were in fact subtly reactive and prompted an emergency craniotomy following

which the patient made a good functional recovery. We argue for the widespread availability of OPs as part of the neurological assessment of head-injured patients amongst all clinicians.

## Case report

A 70-year-old man with a past medical history of atrial fibrillations for which he was prescribed warfarin had an unwitnessed fall while visiting his wife in a nursing home. Initially, he was GCS 15 but subsequently deteriorated to GCS 5 (E1 V1 M3). An ambulance was called and he was taken to the local accident and emergency department, where he was intubated. He was noted to have a dilated and non-reactive right pupil, but the left pupil was at this point still reactive. A CT scan of his brain revealed a large convexity right-sided acute subdural haematoma with 17 mm of midline shift. His warfarin was immediately reversed with Beriplex® and he was also given mannitol. He was transferred directly to the neurosurgical theatres for haematoma evacuation.

On arrival to the anaesthetic room, both pupils were noted to be dilated and non-reactive to light. He had a blood pressure of 200/100 and a heart rate of 41. Given his age and his current neurological and cardiovascular status, he was diagnosed with uncal herniation, brainstem compromise and a non-survivable brain injury. He was therefore transferred to the NeuroICU with a plan to test for brainstem death the following day. However, over the next 2 hours, his pupils were noted to be reacting when tested with an OP – the

**CONTACT** John A. Emelifeonwu  [johnemelifeonwu@gmail.com](mailto:johnemelifeonwu@gmail.com)  Department of Neurosurgery, Western General Hospital, Crewe Road South, Edinburgh EH4 2XU, UK.

Color versions of one or more of the figures in the article can be found online at [www.tandfonline.com/ibij](http://www.tandfonline.com/ibij).

This work has not been previously presented or published in any forum

© 2018 Taylor & Francis Group, LLC

NPi values were 2.6 in the right pupil and 3.8 in the left. This prompted a sedation hold and he was found to be localizing to pain with his left arm. After re-discussion with the neurosurgeons, he was transferred back to theatre for a craniotomy and evacuation of the acute subdural haematoma. He returned to NeuroICU, and over several days, his neurological status improved enough for him to be extubated. He had a residual mild right-sided hemiparesis of both upper and lower limbs and left-sided third cranial nerve palsy. Although mobile, he remained cognitively abnormal and was not fit enough for immediate discharge to home. He was therefore discharged to a neuro-rehabilitation facility.

## Discussion

In the acute phases of TBIs, elevations in ICP can result in inter-compartmental herniation of brain. If the area of neuronal injury is supratentorial, then this can lead to herniation of the medial temporal lobe and uncus through the tentorial incisura – the anterior opening between the free edge of the tentorium cerebelli and the clivus, which permits passage of the brainstem. Thus, the brainstem can become compromised. The anatomical proximity of the third cranial nerve to the medial temporal lobe renders it susceptible to compromise also (Figure 1), and the superficially located parasympathetic fibres, which constrict the pupils, are particularly vulnerable. Herniation of the temporal uncus through the incisura therefore compresses the third nerve and the parasympathetic fibres. It is this anatomy of the third nerve that is exploited by clinicians when assessing pupillary response in the context of TBIs; pupillary dilatation and/or non-reactivity suggest third nerve compromise and should prompt appropriate rescue therapeutic measures. The third nerve nucleus in the midbrain can also be affected in cases of brain stem death.

Pupil size and reactivity therefore provide a useful window to determining whether there is raised ICP in patients with TBI. This is important because patients who are treated promptly, whether medically or surgically after a new pupillary abnormality, have improved recovery potential (5). There are, however, significant inter-assessor differences in

performance and interpretation of the pupillary response, which can be as much as 30% between clinicians, including neurosurgical trainees (3,6). In a clinical context that requires astute clinical assessment and prompt therapeutic actions, the consequences of such inter-user discrepancies can be disastrous. The OP aims to omit these inherent discrepancies. These handheld devices digitally record pupil size and reactivity to infrared light, which is then given a numerical value that is universally interpretable. The evidence for the superiority of OP has been well established, although there is anecdotal evidence of clinicians outperforming OPs in certain clinical settings (7).

## Costs and benefits of OP

Various handheld pupillometry devices exist. In our unit, we use the NeurOptics pupillometer (NeurOptics, Irvine, CA, USA), an infrared system that tracks and analyses pupil dynamics over a 3-second time period. Light of fixed intensity and duration is shone into a pupil, stimulating its light constriction reflex. The measurement lasts 3.2 seconds, and the pupil is tracked and recorded by a digital camera at over 30 frames per second, comparing pupil diameter in each frame to determine the mean and range of standard variation for the eye. Variables including size, latency, constriction velocity and dilation velocity from an individual pupil measurement taken by the OP is compared against the mean of a reference distribution of healthy subjects for the same variable and then standardized by the corresponding standard deviation. Finally, the set of all the standardized differences (or z scores) is combined to fall into a scale set between 0 and 5. This scale set is called an NPi. Generally, an NPi score of 3 or greater means that the pupil reactivity falls within the boundaries of the normative pupil behaviour distribution (8). A score less than 3 denotes an abnormal pupillary light reflex and a score of 0 denotes no reaction. Increasing differences between right and left eye or a decreasing trend in NPi when serially measured can also serve as an indicator of reduced intracranial compliance. Thus, by standardizing pupillary response, the OP aims to provide a simple, accurate and reproducible

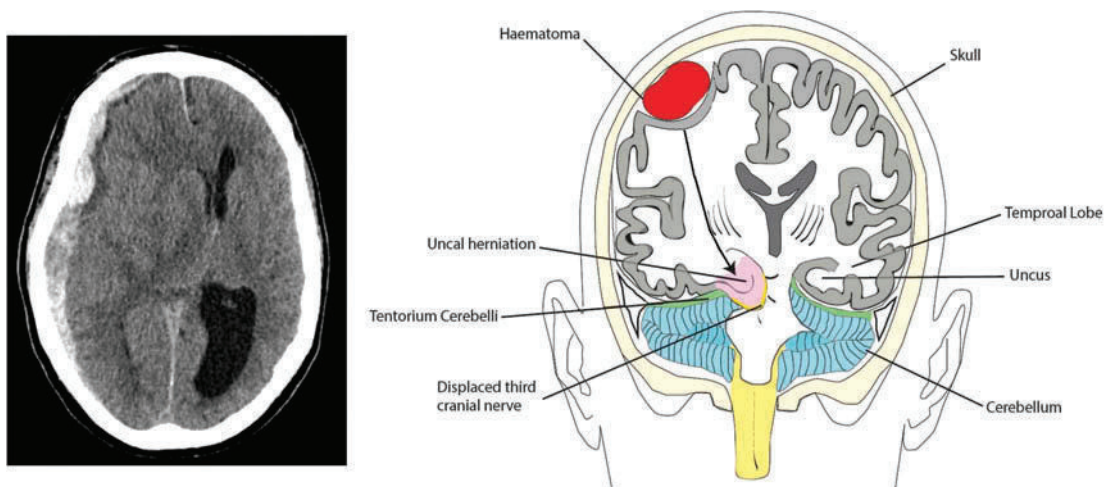


Figure 1. Axial CT scan showing a right-sided acute subdural haematoma with midline shift with a cartoon depiction of resultant uncal herniation.

determinant of pupillary response to light. Despite this, OPs are rarely used in the assessment of patients with head injuries.

One explanation for the slow uptake in the use of OP is the cost it incurs. Besides the costs involved in purchasing the handheld machine (which is approximately £5000 or \$8000), its usage relies on a single-use detachable headrest, which facilitates placement of the OP in front of the eye. This headrest costs approximately £50 or \$80 each. Regular use of OPs would have significant cost implications.

### **An argument for the widespread adoption of NPi**

TBIs are common, with a hospital admission incidence of 235 per 100 000 people in Europe (9) and 1.7 million patients per year being affected in the United States (10). It is a major cause of death and long-term disability, a huge burden on health finances and becoming more common. It follows that many physicians, especially those working in acute settings, are likely to encounter and manage patients with TBIs. Rapid resuscitation and actions to treat raised ICPs improve ICU survival and long-term outcomes (5). The presented case highlights the problem with manual assessments of pupils in the context of TBIs. Assessor factors such as subtle pupil reactions not being appreciated can influence treatment decisions, as was likely the case in the presented patient where a decision not to operate was based on the manual assessment of pupillary light response. The sensitivity of the OP to subtle changes of the pupils to light can reduce such user errors. The NPi provides an easily learnt and reproducible objective assessment of pupillary reactivity much in the same way as the GCS is used to describe injury severity in TBI.

It should be borne in mind that other factors determine pupillary reactivity in the context of TBI. For example, neuroendocrine dysfunction may alter the hypothalamus–pituitary hormonal axis, which in turn can alter sympathetic activity and decrease the pupillary dilating response. Furthermore, variations in pupillary reactivity at different points after injury could be a result of brainstem blood flow, which can vary according to blood pressure changes if auto-regulation is compromised. Finally, seizures are common in the context of TBIs and induce both sympathetic overdrive and neuronal dysfunction, which can manifest as tonic dilatation of the pupils. It is feasible therefore that one or several of these mechanisms may have been active when our patient's pupils were manually checked and it may therefore be the case that the OP may have recorded the pupillary response as abnormal (NPi <3) were it to have been done concurrently with the clinical assessment. To this end, more information on the accuracy of NPi in the context of TBIs is needed and a prospective trial is required to further elaborate on the usefulness of OP in the context of TBIs.

### **Conclusion**

We have presented a case in which the patient was 'saved' by the use of NPi as part of his clinical assessment. This prompted surgery and ultimately a good clinical outcome. The use of the OP, and in particular the NPi, provides a rapid, non-invasive and objective method of assessment in patients with TBI. A prospective trial is required to determine the usefulness of NPi in the assessment of patients with TBIs in the acute setting.

### **Disclosure statement**

The authors report no conflicts of interest. The authors alone are responsible for the content and writing of the article.

### **Sources of financial and material support**

None.

### **References**

1. Andrews BT, Pitts LH. Functional recovery after traumatic tentorial herniation. *Neurosurgery*. 1991;29:227–31. doi:10.1227/00006123-199108000-00010.
2. Lieberman JD, Pasquale MD, Garcia R, Cipolle MD, Li P, Wasser TE. Use of admission Glasgow Coma Score, pupil size and pupil reactivity to determine outcome for trauma patients. *J Trauma*. 2003;55:437–42. doi:10.1097/01.TA.0000081882.79587.17.
3. Kuo JR, Lo CJ, Lu CL, Chio CC, Wang CC, Lin KC. Prognostic predictors of outcome in an operative series in traumatic brain injury patients. *J Formos Med Assoc*. 2011;110:258–64. doi:10.1016/S0929-6646(11)60038-7.
4. Litvan I, Saposnik G, Maurino J, Gonzalez L, Saizar R, Sica RE, Bartko JJ. Pupillary diameter assessment: need for a graded scale. *Neurology*. 2000;54:530–31. doi:10.1212/WNL.54.2.530.
5. Clusmann H, Schaller C, Schramm J. Fixed and dilated pupils after trauma, stroke, and previous intracranial surgery: management and outcome. *J Neurol Neurosurg Psychiatry*. 2001;71:175–81. doi:10.1136/jnnp.71.2.175.
6. Meeker M, Du R, Bacchetti P, Privitera CM, Larson MD, Holland MC, Manley G. Pupil examination: validity and clinical utility of an automated pupillometer. *J Neurosci Nurs*. 2005;37:34–40. doi:10.1097/01376517-200502000-00006.
7. Kramer CL, Rabinstein AA, Wijidicks EF, Hocker SE. Neurologist versus machine: is the pupillometer better than the naked eye in detecting pupillary reactivity. *Neurocrit Care*. 2014;21:309–11. doi:10.1007/s12028-014-9988-5.
8. Chen JW, Gombart ZJ, Rogers S, Gardiner SK, Cecil S, Bullock RM. Pupillary reactivity as an early indicator of increased intracranial pressure: the introduction of the neurological pupil index. *Surg Neurol Int*. 2011;2:82. doi:10.4103/2152-7806.82248.
9. Tagliaferri F, Compagnone C, Korsic M, Servadei F, Kraus J. A systematic review of brain injury epidemiology in Europe. *Acta Neurochir (Wien)*. 2006;148:255–68. doi:10.1007/s00701-005-0651-y.
10. Faul M, Xu L, Wald MM, Coronado VG. Traumatic brain injury in the United States: Emergency department visits, hospitalizations and deaths 2002–2006. Centers for Disease Control and Prevention, National Center for Injury Prevention and Control; 2010. <https://www.cdc.gov/TraumaticBrainInjury>